

Novel dry cryotherapy system for cooling the equine digit

Jessica Morgan, Darko Stefanovski, Margret Lenfest, Sraboni Chatterjee, James Orsini

To cite: Morgan J, Stefanovski D, Lenfest M, *et al.* Novel dry cryotherapy system for cooling the equine digit. *Veterinary Record Open* 2017;0:e000244. doi:10.1136/vetreco-2017-000244

Received 13 July 2017
Revised 6 November 2017
Accepted 11 November 2017

ABSTRACT

Objectives Digital cryotherapy is commonly used for laminitis prophylaxis and treatment. Currently validated methods for distal limb cryotherapy involve wet application or compression technology. There is a need for a practical, affordable, dry cryotherapy method that effectively cools the digit. The objective of this study was to evaluate the hoof wall surface temperatures (HWSTs) achieved with a novel dry cryotherapy technology.

Design Repeated-measures in vivo experimental study.

Setting Experimental intervention at a single site.

Participants 6 systemically healthy horses (3 mares, 3 geldings).

Interventions Cryotherapy was applied to six horses for eight hours with a commercially available rubber and rubber and welded fabric boot, which extended proximally to include the foot and pastern. Reusable malleable cold therapy packs were secured against the foot and pastern with the three built-in hook-and-loop fastener panels.

Primary and secondary outcome measures HWST and pastern surface temperature of the cryotherapy-treated limb, HWST of the control limb and ambient temperature were recorded every five minutes throughout the study period.

Results Results were analysed with mixed-effects multivariable regression analysis. The HWST (median 11.1°C, interquartile range 8.6°C–14.7°C) in the cryotherapy-treated limb was significantly decreased compared with the control limb (median 29.7°C, interquartile range 28.9°C–30.4°C) ($P \leq 0.001$). Cryotherapy limb HWST reached a minimum of 6.75°C (median) with an interquartile range of 4.1°C–9.3°C. Minimum HWST was achieved 68 minutes after cryotherapy pack application.

Conclusions Dry application of cryotherapy significantly reduced HWST and reached minimums below the therapeutic target of 10°C. This cryotherapy method might offer an effective alternative for digital cooling.

INTRODUCTION

Cooling the equine distal limb is a common clinical practice to treat acute laminitis and prevent laminitis in high-risk patients. Distal limb cryotherapy reduces the severity of clinical signs, and in some cases prevents oligofructose-induced laminitis.^{1–4} A large multicentre clinical study of high-risk hospitalised horses also found a decreased incidence of laminitis associated with distal

limb cryotherapy.⁵ Experimental studies showing clinical improvements in laminitis maintained an average hoof temperature of 3.5°C–7.1°C.^{1–3} Based on these studies, and the paucity of data for less extreme cooling, current recommendations are to maintain hoof temperature below 10°C.⁶ The duration of cryotherapy in the experimental setting has ranged from 48 to 72 hours,^{1–3} yet clinical cases are often subject to longer durations of cryotherapy due to ongoing laminitis risk factors. Current recommendations call for continuous distal limb cryotherapy for 24 hours beyond the resolution of clinical signs in horses at risk of developing laminitis and to the resolution of the inflammatory phase in acute laminitis.^{7,8} There is a need for safe, effective, easily applied methods of continuous distal limb cryotherapy for these prolonged treatment periods.

Equine cryotherapy studies that report hoof temperatures below the target of 10°C involve wet applications or compression technology.^{1,2,4,9–11} Although no complications are reported in these cryotherapy studies using wet application methods, there are anecdotal reports of cellulitis, local tissue necrosis and softening of the hoof wall, particularly in horses with concurrent systemic illness.¹² Ice immersion methods also require a convenient source of ice and are labour-intensive. Compression technology avoids prolonged water submersion but can be cost-prohibitive and cumbersome to apply.¹¹ Dry applications offer several potential advantages with ease of application and lack of prolonged tissue submersion.

The purpose of this study was to measure the hoof temperatures achieved using a novel commercially available ice boot and cold therapy packs that are affordable and practical to use in a clinical setting. We hypothesised that hoof wall surface temperatures (HWST) in limbs treated with this dry application ice boot would be lower than in control limbs, with a minimum below the target of 10°C and



CrossMark

Department of Clinical Studies,
New Bolton Center, School of
Veterinary Medicine, University
of Pennsylvania, Kennett Square,
Pennsylvania, USA

Correspondence to

Dr Jessica Morgan; jmmorgan@upenn.edu

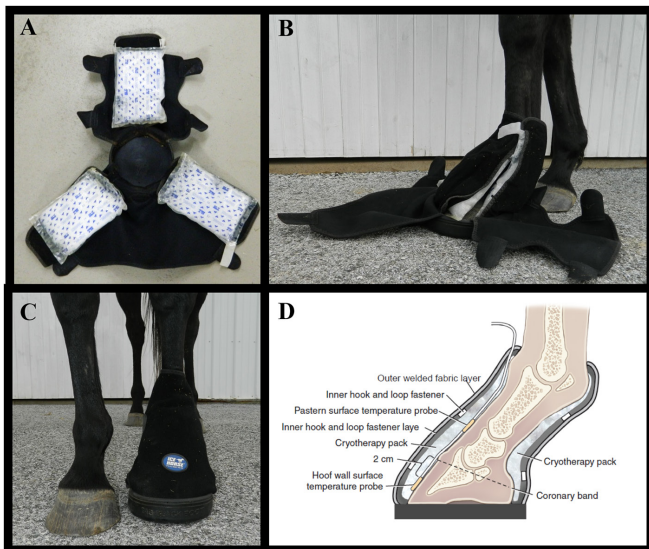


FIG 1: Dry cryotherapy application method using a commercially available boot that encompasses the foot and pastern. Three malleable cryotherapy packs are attached directly to the internal surface of the internal loop and hook fastener layer (A). The packs and internal hook-and-loop fastener layer are then moulded to the hoof and pastern to incorporate the distal limb (B). The boot is finally secured with the outer elastic layer with hook-and-loop fastener flaps (C). Sagittal cut of distal limb demonstrating the arrangement of cryotherapy packs, temperature probes and inner hook-and-loop fasteners secured (D).

below 18.7°C, which is the lowest temperature reported for other dry cryotherapy methods.¹¹

MATERIALS AND METHODS

This prospective study was performed with six horses (three geldings and three mares) 2–26 (median 14.5) years of age and of various breeds (two Thoroughbreds, two Warmbloods, one Standardbred and one Friesian) from the university research herd with no evidence of systemic disease on physical examination. The horses weighed between 510 and 659 (median 557) kilograms (kg). Horses were instrumented with temperature probes (Surface Thermistor Probe PB-5003; Gemini Data Loggers, Chichester, West Sussex, UK) on both forelimbs. The HWST probes were secured with adhesive tape on dorsal midline 2 cm distal to the coronary band of the control and treated hooves as previously described.¹¹ The relative position of the temperature probe, boot and cryotherapy pack is illustrated in Fig 1. Additional probes were adhered to the clipped dorsal pastern of the cryotherapy treatment limb using cyanoacrylate (Vetbond; 3M Animal Care Products, St Paul, MN, USA) around the borders of the temperature probe and placed outside the stall to record ambient temperature. HWST, dorsal pastern temperature and ambient temperature probes were attached to data logging devices (Tinytag; Gemini Data Loggers (UK)) to record temperature every five minutes throughout the eight-hour study period. The forelimbs

were exclusively used in this study due to the presence of data supporting the clinical use of cryotherapy for laminitis in forelimbs⁵ and the ability to compare with previously evaluated cryotherapy methods.¹¹ During the trial, horses were cross-tied in a stall to prevent temperature probes from coming dislodged. Horses were sedated with intravenous xylazine hydrochloride (X-ject E Injection; Henry Schein, Dublin, OH, USA) ± acepromazine maleate (Aceproject; Henry Schein) as needed to facilitate accurate temperature probe and boot placement. A single horse received no sedation, two horses received a single dose of xylazine alone (0.25–0.26 mg/kg), and three horses received a combination of xylazine (total dose 0.28–0.55 mg/kg, median 0.28) and acepromazine (total dose 0.03–0.16 mg/kg, median 0.04). Horses were housed in a temperature-controlled barn, with the exception of one horse that was housed in a non-temperature-controlled barn due to logistical constraints. Free choice hay and water were available to the horses throughout the study, and horses were continually monitored throughout the eight-hour trial. At the completion of the trial, horses were evaluated with digital palpation and visual examination at rest and during walk.

Cryotherapy application

Each horse underwent a single cryotherapy trial between June and August 2016 that started in the morning and lasted eight hours. The left front foot was placed in a commercially available rubber and welded fabric ice boot (Big Black Boot; Henry Schein), which extended proximally to include the pastern (Fig 1), without an acclimation period. Reusable cryotherapy packs (Cold Capsule Technology; Ice Horse, MacKinnon Products, Sonoma, CA, USA) were cooled in a standard residential style freezer (approximately –20°C) overnight and re-cooled for a minimum of two hours before reuse. Cryotherapy packs were secured against the foot with the three built-in hook-and-loop fastener panels such that the cryotherapy pack was in direct contact with the limb (Fig 1). The cryotherapy packs (Cold Capsule Technology; Ice Horse, MacKinnon Products) are commercially available with the boot (Ice Horse, MacKinnon Products). These cryotherapy packs consist of a casing made from biaxially oriented nylon film of polyamide resin and linear low-density polyethylene filled with a freezable mixture of water, propylene glycol, triethanolamine 99 per cent, polyacrylic acid and quaternium-15. This design was modified from previous cold therapy packs used by the company to provide dry contact cryotherapy to the foot and pastern region with a malleable ice pack, which allows intimate contouring to the limb. After initial overnight freeze, two sets of three cryotherapy packs were used in each trial, alternating them between the freezer and the cryotherapy boot every two hours. This resulted in replacement of the cryotherapy packs every two hours throughout the study. In an *in vitro* trial, cryotherapy packs (n=6) were frozen overnight, then instrumented with a surface temperature probe (Surface Thermistor

Probe PB-5003; Gemini Data Loggers (UK)) adhered to the surface, which would be in contact with the hoof wall when placed in the boot, to measure surface temperature. Temperature was recorded every five minutes during a 15-minute period, after removing the cryotherapy packs from the freezer and during refreezing after a two-hour application. These trials were performed with a set of three cryotherapy packs on two separate occasions.

Data analysis

Descriptive data analysis and mixed-effects linear multivariable regression analysis were performed using commercially available statistical software (Prism, GraphPad Software, San Diego, CA, USA; and STATA 14, StataCorp, College Station, TX, USA). A Mann-Whitney test was used to compare cryotherapy pack temperatures after overnight and two-hour freezes. Multivariable linear regression analysis was selected in order to allow time to be considered as a continuous variable and to account for variation in ambient temperature. The outcome variables were forelimb distal limb temperatures (HWST and cryotherapy limb pastern surface temperature). The primary predictor variable of interest was cryotherapy treatment (yes/no). Ambient temperature, time and cryotherapy pack replacement were included as potential confounders. Cryotherapy pack replacement was a categorical variable (yes/no), defined as a 10-minute window when the cryotherapy packs were exchanged. The random effects were assigned on the level of the animal. Statistical significance was defined as $P \leq 0.05$. Non-compartmental pharmacokinetic analysis (NCA) was used to establish the minimal temperatures and time to minimal temperature during each cryotherapy pack application period. Descriptive data are reported as median \pm interquartile range (IQR) unless otherwise stated. Data from regression or non-compartmental analysis are reported as ± 95 per cent confidence interval unless otherwise stated.

RESULTS

Cryotherapy was well tolerated and no adverse effects were noted at any point in the study. There was a single instance where the cryotherapy boot required resetting five minutes before scheduled cryotherapy pack replacement due to displacement of the boot relative to the hoof. Displacement of the boot did not disrupt data collection. Data were available for all sensors throughout the study period with the exception of the initial 30 minutes of the cryotherapy limb data in one trial, due to technical malfunction. Cryotherapy pack surface temperature after overnight freezing was $-14.2 \pm 2.3^\circ\text{C}$. Surface temperature quickly warmed to $7.65^\circ\text{C} \pm 2.6^\circ\text{C}$ 10 minutes after removal from the freezer. After a two-hour refreezing period between uses, surface temperature reached $-6.7 \pm 0.9^\circ\text{C}$, which was significantly warmer ($P < 0.001$) than after an overnight freeze. Descriptive temperature data are summarised in Table 1. The data from the horse that was not housed in the temperature-controlled barn was

TABLE 1 Summary of temperatures ($^\circ\text{C}$) for the cryotherapy treated limb, control limb and ambient conditions ($n=6$) during eight hours of cryotherapy

	Median	Interquartile range
Cryotherapy limb		
HWST	11.1	8.6–14.7
Minimum HWST	6.8	4.9–8.2
Maximum HWST (1–8 hours)	22.0	19.7–27.4
Pastern temperature	16.8	12.9–23.5
Minimum pastern temperature	9.9	6.4–16.4
Maximum pastern temperature (1–8 hours)	29.9	24.7–30.2
Control limb		
HWST	29.7	28.9–30.4
Minimum HWST	28.1	25.7–29.2
Maximum HWST (1–8 hours)	30.4	30.3–32.9
Ambient temperature	21.4	20.7–22.1

HWST, hoof wall surface temperature.

included in subsequent analysis based on the relatively low HWST (median 7.5°C , IQR 6.0°C – 9.3°C) despite the relatively high ambient temperature during that trial (median 28.6°C , IQR 26.2°C – 29.7°C). Ambient temperature is correlated with distal limb temperatures ($P < 0.001$), with an increase of 0.5°C in distal limb temperature per degree increase in ambient temperature. Results of the multivariate analysis are summarised in Table 2.

TABLE 2 Final results of mixed-effects linear multivariable regression analysis of distal limb temperatures in cryotherapy-treated limbs compared with control limb HWST ($n=6$)

Variable	Coefficient	95% CI	P value
Ambient temperature	0.491	0.282 to 0.699	≤ 0.001
Time	-0.003	-0.005 to -0.002	≤ 0.001
Treatment			
Cryotherapy HWST	-17.964	-18.487 to -17.441	≤ 0.001
Cryotherapy pastern temperature	-12.596	-13.118 to -12.074	≤ 0.001
Ice replacement			
>10 minutes of replacement	1.468	0.713 to 2.256	≤ 0.001
Constant	19.759	14.730 to 24.768	≤ 0.001

The outcome variables are distal limb temperature (HWST and pastern surface temperature) as measured in $^\circ\text{C}$. HWST, hoof wall surface temperature.

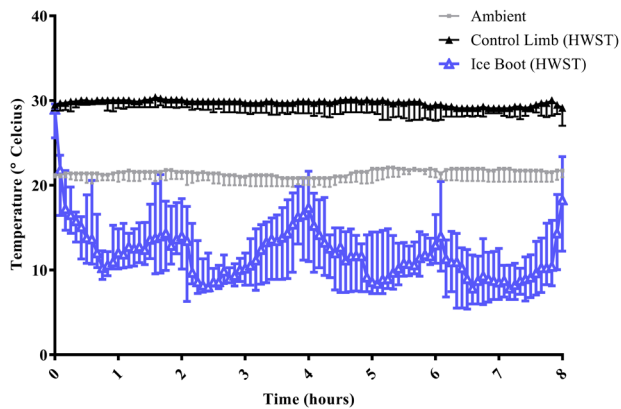


FIG 2: Hoof wall surface temperatures (HWST) over eight hours in cryotherapy-treated and control limbs of six healthy horses. Data points represent median \pm interquartilerange.

The HWST in the cryotherapy-treated limb was $18.0^{\circ}\text{C}\pm 0.52^{\circ}\text{C}$ lower than in the control limb ($P<0.001$) (Fig 2). Pastern surface temperature was increased by $5.37^{\circ}\text{C}\pm 0.53^{\circ}\text{C}$ compared with HWST in the cryotherapy treated limb ($P<0.001$) (Tables 1 and 2). Occasional temperature spikes were observed in the cryotherapy treated limb, which were strongly associated with cryotherapy pack replacement ($P\leq 0.001$). The HWST of the cryotherapy-treated limb was below 10°C for a median of 170 minutes (IQR 44–396 minutes) during the 480-minute study period. The control limb HWST did not fall below 10°C .

NCA using a pharmacokinetics approach was performed to look at the effects of cryotherapy pack application over time. The minimal HWST reached during the initial cooling period (0–2 hours) was $10.0^{\circ}\text{C}\pm 1.6^{\circ}\text{C}$ and the time to minimal temperature was 68.7 ± 20.3 minutes. Cryotherapy packs were changed at the end of each two-hour cooling period. Minimum HWST was lower than the initial cooling period in all subsequent cooling periods, reaching $7.9^{\circ}\text{C}\pm 1.6^{\circ}\text{C}$, $8.6^{\circ}\text{C}\pm 1.6^{\circ}\text{C}$ and $6.9^{\circ}\text{C}\pm 1.6^{\circ}\text{C}$, respectively, during the second, third and fourth cooling period. HWST was significantly lower than the initial period during the second and fourth cooling period ($P=0.007$, $P\leq 0.001$).

DISCUSSION

Dry distal limb cryotherapy achieved a minimum HWST below the suggested target of 10°C in all horses during this study. This is in contrast with previous reports, which found that dry cryotherapy methods without active circulation and compression did not achieve HWSTs below 10°C .^{10,11} Several previous evaluations of dry cryotherapy methods found minimal decrease in hoof temperature. Median HWSTs of 19.9°C are reported for a cooling gel wrap applied to the hoof wall, fetlock and metacarpus.¹¹ A separate evaluation of a gel pack ice boot applied to the distal limb was not able to detect significant cooling

compared with the control limb and maintained a mean laminar temperature of 33.4°C .¹⁰ In contrast, our study documented significant cooling in the cryotherapy-treated limb compared with the control, with a median HWST of 11.1°C ($P<0.001$) and all horses reaching a minimum below 10°C . This represents a marked improvement over the median of 19.9°C reported with other dry application systems under similar ambient temperatures.¹¹

Variation in hoof temperature assessment can complicate cryotherapy study comparisons. This study used HWST and pastern surface temperature as non-invasive measures of distal limb cooling. HWST is an indirect measure of lamellar temperature and can be affected by ambient temperature, as well as physiological characteristics of the limb.¹³ Previous studies that documented reduced lamellar injury and inflammatory signal inhibition reported average HWSTs of 7.1°C and 4.2°C .^{3,4} HWSTs and internal hoof wall or laminar temperatures have not been directly compared. When independent studies using similar cooling methods but different methods of hoof temperatures assessment are compared, HWST and internal hoof wall temperature have been within 1°C .^{1,3} If HWST is compared across independent studies in healthy horses, HWST is slightly lower (median 5.9°C) than reported lamellar ($11.14^{\circ}\text{C}\pm 1.7^{\circ}\text{C}$) or internal hoof wall ($11.9^{\circ}\text{C}\pm 1.0^{\circ}\text{C}$) temperatures with similar cryotherapy methods.^{9–11} This discrepancy may reflect differences in the correlation between HWST and internal temperature associated with disease state or be a result of variability in methods across studies. In this study, a potential source of variability in HWST was the variable low-dose sedative protocols used, which were dependent on patient behaviour. Although HWST may not reflect internal lamellar temperature under all conditions, the existing literature supports its use as an indirect measure of lamellar temperature. Variations in temperature measurement are unlikely to fully account for the variable results observed with dry cryotherapy methods.

Although continuous distal limb cryotherapy has been shown to prevent or ameliorate the development of laminitis,^{1–3,5} the digital temperatures required to achieve this protective effect are unknown. Effective methods used previously achieved temperatures below 8°C and used wet applications under experimental conditions.^{2–4,9–11} The fluid bag immersion method, which was effective at laminitis prevention in a multicentre retrospective study, resulted in HWST below 7.8°C when evaluated in four clinically normal horses.^{5,11} Based on these studies the current recommendations suggest targeting 10°C , as studies evaluating the effects of less extreme distal limb cryotherapy in horses are currently lacking.⁶ The cryotherapy method evaluated in this study is a marked improvement over previously tested dry cryotherapy methods. Although the method does not sustain the HWST below 10°C , documenting even transient HWST below 10°C is a significant improvement in available dry cryotherapy methods.

The therapeutic value of dry cryotherapy methods, which offer less extreme cryotherapy with increased variability compared with wet immersion methods, remains an open question in the treatment of laminitis. In human beings, moderate systemic hypothermia (decreasing core temperature by only 5°C–10°C) can be beneficial, improving neurological, cardiac and survival outcomes in diseased individuals.^{14–16} Hypothermia has multiple effects in tissue that may explain its disease-modifying effects in equine laminitis, including the induction of vasoconstriction, modulation of inflammatory tissue damage and decreasing metabolic rate.⁸ In animal models, moderate local hypothermia (reduction of 8°C–11°C) was sufficient to induce vasoconstriction of greater than 40 percent and decrease osseous perfusion.^{17,18} Moderate hypothermia (reduction of 5°C) was also sufficient to reduce endotoxin-induced lung injury, supporting its effect in modulating inflammatory tissue damage.¹⁹ Finally, even modest decreases in temperature can substantially reduce metabolic rate. Metabolic activity is generally reported to reduce approximately 50 per cent for a 10°C reduction in temperature.²⁰ Studies evaluating temperature fluctuations in human beings were not able to document any effect of fluctuations on neurological outcomes, but no such data are available for laminitis.²¹ Further studies in horses are needed to determine if mild or variable hypothermia is sufficient to prevent the onset of laminitis. Based on the available literature in other species, the cryotherapy method evaluated in this study has potential prophylactic and therapeutic benefits in the management of laminitis, despite some temperature fluctuations, by virtue of its ability to achieve a temperature decrease of 18°C compared with control limbs.

The improved efficacy of this dry cryotherapy method compared with previously tested dry cryotherapy methods, including that used by van Eps and Orsini in 2016, is likely attributable to several modifications to previous dry cryotherapy boots, as the ambient conditions and temperature monitoring methods were similar between the two studies. The modifications include that the boot and the cryotherapy packs used in this study extend proximally to incorporate the pastern, and the material within the cryotherapy packs has been redesigned to easily conform to the limb. Pastern surface temperature was measured in the cryotherapy limb in this study to document precooling of the limb proximal to the hoof. The pastern surface temperatures were consistently decreased but remained 5°C above the HWST in treated limbs. The continued drop in temperature distally suggests that this method achieves both precooling and direct cooling of the hoof wall. The cryotherapy packs used in this study, the arrangement of the malleable cryotherapy packs in intimate contact with the limb and incorporation of the pastern (Fig 1) may have contributed to the improved efficacy.

The cryotherapy method used in this study has the advantage of avoiding tissue submersion, the need for ready access to free ice and the cumbersome proximal

attachments associated with other currently validated methods, while still achieving a median HWST of 11.1°C with minimums below 10°C in the treated hoof. Potential complications of dermatitis, cellulitis, tissue necrosis, limb oedema and softening of the hoof wall have been anecdotally reported in horses with continuous immersion methods.¹² Similar complications including dermal lesions, pain and oedema known as non-freezing cold injury or ‘immersion foot’ have been reported in military and homeless populations that experience prolonged exposure to cold wet environments.^{22–24} Although the focal temperature at the surface of the cryotherapy pack during the initial 5–10 minutes of this cryotherapy method was potentially quite low (below 7.65°C±2.6°C observed at 10 minutes), no complications associated with focal tissue damage were observed in this study. Dry applications offer the advantage of avoiding direct skin contact with ice and prolonged immersion in water and allowing regular inspection of the limb with cryotherapy pack replacement, while achieving significant decreases in HWST.

The specifics of this cryotherapy protocol including the frequency of cryotherapy pack changes and the freezing protocols will need to be balanced with the practical concerns of cryotherapy pack purchases and labour to rotate the cryotherapy packs. In this study, with cryotherapy pack changes every two hours, a nadir in HWST occurred 68.7±20.3 minutes after cryotherapy pack application, with the minimums decreasing during later applications. Data analysis supports that cryotherapy pack changes every hour would hasten reaching steady state at the lower HWSTs reached later in the study. Cryotherapy packs were used in an alternating fashion in this study such that the pack was used for two hours and then cooled for two hours. Although this was sufficient to result in significant cooling, and may be a practical approach, the packs did not reach the same temperature after two hours of recooling as they did overnight. It is possible that cooling efficacy could be further improved by using longer recooling times. The temperature variability in the cryotherapy method used in this study could also potentially be further reduced by increasing the frequency of cryotherapy pack replacement to every hour before gradual rewarming can occur. The boots used in this study were all of one size despite a range of hoof sizes in the study horses. Boot displacement could potentially be reduced and contact improved by using a range of boot sizes, which have become available since the completion of this study. Future studies are indicated to confirm the value of more frequent ice pack changes, effects of boot fit and cryotherapy pack freezing protocols relative to the financial and labour investments required.

In conclusion, this dry cryotherapy method effectively reduced HWST and reliably reached minimums below 10°C, an improvement compared with HWSTs previously reported with similar systems. Based on evaluation of the data, increasing the frequency of cryotherapy pack replacement and adapting cryotherapy pack handling

protocol have the potential to further stabilise the lower HWST. Future studies are indicated to optimise treatment protocols and determine if this type of cryotherapy is clinically effective at preventing and treating laminitis.

Acknowledgements The authors would like to acknowledge Jennifer Wrigley, CVT, RN, for technical assistance throughout the study.

Contributors JO designed and executed the study. JM and JO contributed to data analysis, interpretation and preparation of the manuscript. DS contributed to data analysis, interpretation and manuscript preparation. ML and SC assisted in study execution, data collection and interpretation of results. All authors approved the final manuscript.

Funding Thoroughbred Education and Research Foundation, Roemer Foundation and Spot Castle Memorial Fund.

Competing interests The ice boot and packs were provided by MacKinnon Products as an in-kind donation. The company had no input in study design, execution, data analysis or manuscript preparation.

Ethics approval All procedures were approved by the Institutional Animal Care and Use Committee (IACUC protocol #804565).

Provenance and peer review Not commissioned; externally peer reviewed.

Data sharing statement The raw data from individual cryotherapy trials are available upon request. To request this information please contact Jessica Morgan by email at jimmorgan@upenn.edu.

Open Access This is an Open Access article distributed in accordance with the Creative Commons Attribution Non Commercial (CC BY-NC 4.0) license, which permits others to distribute, remix, adapt, build upon this work non-commercially, and license their derivative works on different terms, provided the original work is properly cited and the use is non-commercial. See: <http://creativecommons.org/licenses/by-nc/4.0/>

© British Veterinary Association (unless otherwise stated in the text of the article) 2017. All rights reserved. No commercial use is permitted unless otherwise expressly granted.

REFERENCES

- van Eps AW, Pollitt CC. Equine laminitis: cryotherapy reduces the severity of the acute lesion. *Equine Vet J* 2004;36:255–60.
- van Eps AW, Pollitt CC. Equine laminitis model: cryotherapy reduces the severity of lesions evaluated seven days after induction with oligofructose. *Equine Vet J* 2009;41:741–6.
- van Eps AW, Leise BS, Watts M, *et al.* Digital hypothermia inhibits early lamellar inflammatory signalling in the oligofructose laminitis model. *Equine Vet J* 2012;44:230–7.
- van Eps AW, Pollitt CC, Underwood C, *et al.* Continuous digital hypothermia initiated after the onset of lameness prevents lamellar failure in the oligofructose laminitis model. *Equine Vet J* 2014;46:625–30.
- Kullmann A, Holcombe SJ, Hurcombe SD, *et al.* Prophylactic digital cryotherapy is associated with decreased incidence of laminitis in horses diagnosed with colitis. *Equine Vet J* 2014;46:554–9.
- van Eps AW. Acute laminitis: medical and supportive therapy. *Vet Clin North Am Equine Pract* 2010;26:103–14.
- Divers TJ. Clinical Application of Current Research Findings Toward the Prevention and Treatment of Acute Laminitis in Horses With Systemic Inflammatory Diseases: An Internist's Perspective. *J Equine Vet Sci* 2010;30:517–24.
- van Eps AW. Therapeutic hypothermia (cryotherapy) to prevent and treat acute laminitis. *Vet Clin North Am Equine Pract* 2010;26:125–33.
- Pollitt CC, van Eps AW. Prolonged, continuous distal limb cryotherapy in the horse. *Equine Vet J* 2004;36:216–20.
- Reesink HL, Divers TJ, Bookbinder LC, *et al.* Measurement of digital laminar and venous temperatures as a means of comparing three methods of topically applied cold treatment for digits of horses. *Am J Vet Res* 2012;73:860–6.
- van Eps AW, Orsini JA. A comparison of seven methods for continuous therapeutic cooling of the equine digit. *Equine Vet J* 2016;48:120–4.
- Geor RJ. *Equine laminitis*. New Jersey: John Wiley & Sons, 2017.
- Hood DM, Wagner IP, Brumbaugh GW. Evaluation of hoof wall surface temperature as an index of digital vascular perfusion during the prodromal and acute phases of carbohydrate-induced laminitis in horses. *Am J Vet Res* 2001;62:1167–72.
- Pfister RH, Soll RF. Hypothermia for the treatment of infants with hypoxic-ischemic encephalopathy. *J Perinatol* 2010;30 :S82–S87.
- Schenone AL, Cohen A, Patarroyo G, *et al.* Therapeutic hypothermia after cardiac arrest: A systematic review/meta-analysis exploring the impact of expanded criteria and targeted temperature. *Resuscitation* 2016;108:102–10.
- Martirosyan NL, Patel AA, Carotenuto A, *et al.* The role of therapeutic hypothermia in the management of acute spinal cord injury. *Clin Neurol Neurosurg* 2017;154:79–88.
- Thorlaciuss H, Vollmar B, Westermann S, *et al.* Effects of local cooling on microvascular hemodynamics and leukocyte adhesion in the striated muscle of hamsters. *J Trauma* 1998;45:715–9.
- Venjakob AJ, Vogt S, Stöckl K, *et al.* Local cooling reduces regional bone blood flow. *J Orthop Res* 2013;31:1820–27.
- Chin JY, Koh Y, Kim MJ, *et al.* The effects of hypothermia on endotoxin-primed lung. *Anesth Analg* 2007;104:1171–8.
- Zachariassen KE. Hypothermia and cellular physiology. *Arctic Med Res* 1991;50(Suppl 6):13–17.
- Nayeri A, Bhatia N, Holmes B, *et al.* Temperature variability during targeted temperature management is not associated with neurological outcomes following cardiac arrest. *Am J Emerg Med* 2017;35:889–92.
- Wrenn K. Immersion foot. A problem of the homeless in the 1990s. *Arch Intern Med* 1991;151:785–8.
- Nagarajan S. Cold weather injuries, active and reserve components, U.S. Armed Forces, July 2010–June 2015. Medical Surveillance Monthly Report. 2010; 7–12.
- Whitaker J. Non-freezing cold injury, lessons from history for future prevention. *Trauma* 2016;18:178–85.